iMEDiTEC 2017

ORIGINAL PAPER

Grayscale Assessment of Low-Field Magnetic Resonance Imaging of Articular Cartilage in Synovial Joint

R. Seeni Ibramsa [a], M. J. Abd Latif [a,b,*], N. H. Mohd. Saad [b,c], N. Sanusi [a], S. M. Idrus Alhabshi [d], M. R. Abdul Kadir [e]

[a] *Faculty of Mechanical Engineering, Universiti Teknikal Malaysia Melaka, Hang Tuah Jaya, 76100 Durian Tunggal, Melaka, Malaysia*
[b] *Centre for Robotics & Industrial Automation (CERIA), Universiti Teknikal Malaysia Melaka, Hang Tuah Jaya, 76100 Durian Tunggal, Melaka, Malaysia*
[c] *Faculty of Electronics and Computer Engineering, Universiti Teknikal Malaysia Melaka, Hang Tuah Jaya, 76100 Durian Tunggal, Melaka, Malaysia*
[d] *Department of Radiology, Faculty of Medicine, Universiti Kebangsaan Malaysia Medical Centre, Jalan Yaacob Latif, Bandar Tun Razak, 56000 Cheras, Kuala Lumpur, Malaysia*
[e] *Faculty of Bioscience and Medical Engineering, Universiti Teknologi Malaysia, 81310 UTM Skudai, Johor Darul Takzim, Malaysia*

* *Corresponding author: juzaila@utem.edu.my*

ABSTRACT

Magnetic resonance imaging (MRI) has become the most potential imaging technique to assess the condition of the articular cartilage. However, most of the previous studies of articular cartilage were performed using high-field MRI systems. Although the low-field MRI had been utilized to measure the geometrical data of cartilage, its capabilities on examining the articular cartilage are yet to be explored. Therefore, the aimed of this study is to investigate the potential used of low-field MRI to examine the cartilage tissue based on the MRI image grayscale value. Various imaging sequences from the low-field MRI system were used to scan the bovine hip joint to assess the articular cartilage. The images generated from the gradient echo and spin echo T1 imaging sequences provide sufficient image quality and grayscale data throughout the cartilage. This could indicate the ability of low-field MRI to evaluate the physiological characteristics of the cartilage tissue using the image grayscale.

INTRODUCTION

Osteoarthritis (OA) is the most common joint disease and symptomatic health problem to middle age and older people. The early symptom of OA is the limitation of joint movement in daily activities which then leads to chronic joint (Moore and Burris, 2015; Hassanali and Oyoo, 2011). Although there are various causes of OA, it is well recognized that the degeneration of articular cartilage tissue in synovial joint is the main cause of OA (Egloff *et al.*, 2012; Buckwalter and Martin, 2006).

Articular cartilage is a biphasic tissue consists of solid and fluid phases which acts as shock absorption, provision of low-friction gliding surface and load-bearing surface for efficient joint articulation in synovial joint (Meng *et al.*, 2017; Iwamoto *et al.*, 2013). The tissue mainly composed of 70-80% water while the remaining solid phase composed of proteoglycans and collagen fibrils composition (Fox *et al.*, 2009; Hosoda *et al.*, 2009). The water content and proteoglycan concentration changes throughout the depth of cartilage tissue to restrain the macromolecular environment within the tissue (Gannon *et al.*, 2012; Liess *et al.*, 2002). The degeneration of the macromolecular constituents in articular cartilage affects the mechanical properties of the tissue.

Although there are various methods used to examine and diagnose the OA disease, magnetic resonance imaging (MRI) is known as the epitome for non-invasive diagnosis in tissue imaging due to the excellent soft tissue contrast (Crema *et al.*, 2011). Generally, the field strength of MRI can be classified into low (<1.5 T), high (1.5-7.0 T), and ultra-high (>7.0 T). However, most of the studies were carried out using high-field MRI unit to examine articular cartilage properties since these MRI units were clinically used to diagnose patients (Gold *et al.*, 2009; Blumenkrantz and Majumdar, 2007; Braun and Gold, 2012). Moreover, the purchase and maintainance costs of high-field MRI is much higher as compared to low-field MRI (Bürk *et al.*, 2015; Tavernier and Cotten, 2005; Kersting-Sommerhoff *et al.*, 1996).

In previous studies, low-field MRI units were only used to quantify the morphology of articular cartilage to measure the thickness, volume and joint space (Olive, 2010; Eckstein *et al.*, 2006; Raynauld, 2003). However, the capabilities of the low-field MRI on examining the articular cartilage are yet to be explored. Moreover, low-field MRI has shown the potential of producing similar image quality of high-field MRI (Cotten *et al.*, 2000). Therefore, the aimed of this study is to investigate the potential used of low-field MRI system to examine the cartilage tissue based on the image grayscale assessment. The outcome of this study could be used to increase the effectiveness to detect the degenerated articular cartilage at an early stage using low-field MRI.

MATERIALS AND METHOD

Specimen preparation

Bovine hip joints (n=6) were obtained within 24 hours after slaughter from a local abattoir. Excess ligaments and flesh of the joint were discarded as shown in Fig. 1. The specimens were then stored at 7°C in moist condition within 48 hours prior scanning.

OPEN ACCESS Freely available online
eISBN 978-967-0194-93-6 FBME

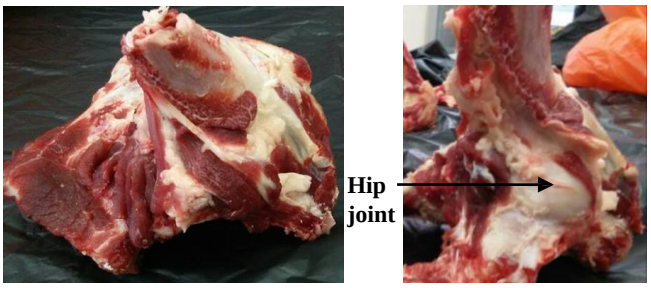

Fig. 1 Intact bovine hip joint.

Low-field magnetic resonance imaging

The hip joints were imaged using 0.18 T low-field MRI system (Esaote C-Scanner, Genova, Italy) in which the position was set at the middle of the MRI coil with the lower hip bone was 180° flexion. Five imaging sequences available in the MRI system were used to evaluate the image quality of the cartilage generated from the system which were the gradient echo (GE), gradient echo short-T1 inversion recovery (GE-STIR), spin echo T1 (SE-T1), spin echo T2 (SE-T2) and turbo spin echo (Turbo SE). The parameters of the imaging sequences are tabulated in Table 1.

Table 1 Imaging parameters of low-field MRI sequences.

Parameters	Sequences				
	GE	GE STIR	SE T1	SE T2	Turbo SE
TE (ms)	18	16	26	90	90
TR (ms)	2660	2400	2900	4940	4940
No. of Slices	31	31	31	31	31
FOV (mm)	180	180	180	180	180
Matrix	256	256	256	256	256
Thickness (mm)	4	4	4	4	4

Grayscale assessment of low-field MRI image

The cartilage image was segmented based on the region of interest (ROI) of 6×3 pixel matrix at four areas of the femoral head as shown in Fig. 2. The grayscale values of each pixel were determined using MATLAB software (MathWorks Inc., MA, USA).

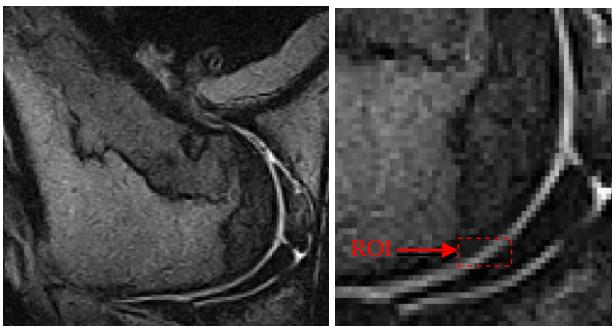

(a) (b)

Fig. 2 (a) Low-field MRI image of bovine hip joint, (b) Cartilage region of interest (ROI).

Statistical analysis

The grayscale of the MRI images were statistically evaluated using t-test assuming unequal variances ($p<0.05$). This is to evaluate the statistical significance of the imaging sequence which to be used for cartilage tissue.

RESULTS AND DISCUSSION

Imaging sequence of cartilage

The articular cartilage images from five different imaging sequences of the low-field MRI system are shown in Fig. 3. Based on the images, GE and SE-T1 imaging sequences show clear and better image quality of cartilage compared to other sequences. These imaging sequences were also used in previous studies using low-field MRI systems to image the articular cartilage due to the better definition of the anatomic structure of the synovial joint and maximizes the signal and contrast between the joint structures (Pujol *et al.*, 2011; Arencibia *et al.*, 2015). Hence, both of this sequences could be utilized to examine the morphology of articular cartilage such as cartilage thickness, volume and joint space.

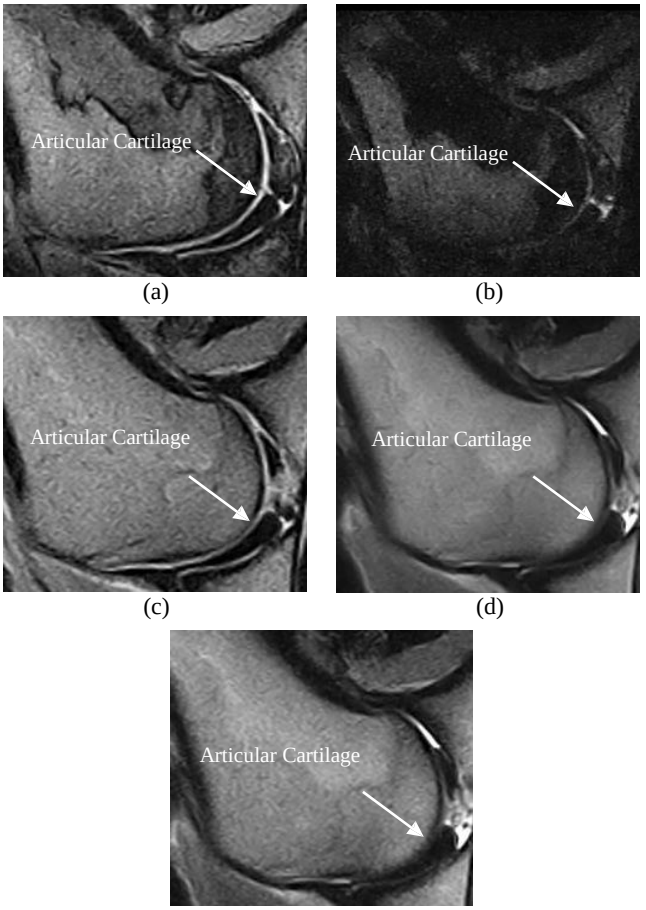

(a) (b) (c) (d) (e)

Fig. 3 Articular Cartilage MRI Images from Different Imaging Sequences; (a) GE, (b) GE-STIR, (c) SE-T1, (d) SE-T2, and (e) Turbo SE

Grayscale assessment

Cartilage images generated from GE and SE-T1 imaging sequences were analyzed to assess the grayscale intensity. Different range of grayscale values were obtained at the same ROI where the average grayscale for GE was 1287.41±399.72 and SE-T1 was 1218.25±460.63. Although the difference between the average grayscale was comparable with only 5.37% difference, higher grayscale deviation was generated by the SE-T1 imaging sequence.

Further statistical t-test analysis was carried out to evaluate the statistical significance between the two imaging sequences. It was found that the grayscale generated from the GE imaging sequence was statistically significance ($p=0.03$) as compared to SE-T1 imaging sequence. Therefore based on the image and the grayscale value analysis, the GE imaging sequence was observed to be the reliable imaging sequence in order to assess the articular cartilage using using the present low-field MRI system.

In the present study, two layers of pixel at the cartilage region were obtained from the MRI images. This is due to the plane

resolution of the image was 0.70 mm and the average thickness of the cartilage was 1.40±0.18 mm. These two layers can be categorized as superficial zone and deep zone of the cartilage. The average grayscale of the superficial zone and deep zone was found to be 1655.14±481.82 and 1129.45±453.94 respectively as shown in Fig. 4. The grayscale of the superficial zone was 31.8% higher compared to the deep zone.

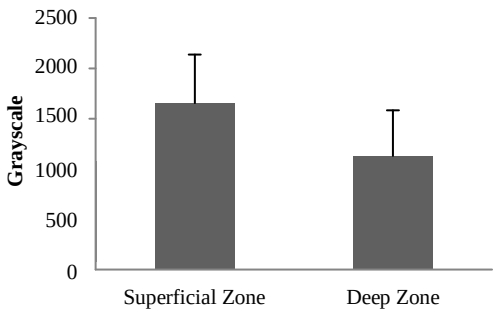

Fig. 4 Grayscale average and standard deviation range of the superficial and deep zones.

Higher grayscale of articular cartilage at the superficial zone compared to deep zone could be due to the water content where studies have shown that higher water content was found in superficial zone in cartilage (Iwamoto *et al.*, 2013; Fox *et al.*, 2009). The articular cartilage is a stratified tissue which contains different composition and structure throughout the thickness of the tissue. The ability of articular cartilage to perform its physiological functions depends on the structure, the composition and the integrity of its extracellular matrix (ECM) as the matrix generates the tensile and compressive stiffness of the cartilage (Iwamoto *et al.*, 2013; Fox *et al.*, 2009).

Similar trend was also observed using high-field MRI between the grayscale stratification and the zones in the cartilage where higher signal intensity at the superficial zone was generated compared to the zone closer to the tidemark and subchondral bone for normal cartilage (Eckstein *et al.*, 2006; Kersting-Sommerhoff *et al.*, 1996). This could indicate that the low-field MRI has the potential to evaluate different physiological characteristics throughout the thickness of the articular cartilage using the image grayscale.

CONCLUSION

This study presented the application of low-field MRI to assess the articular cartilage. The GE is the most reliable imaging sequence in the present low-field MRI system which produced good quality image of cartilage tissue. It capable to generate grayscale data throughout the cartilage thickness and shows the ability to evaluate the physiological characteristics of the cartilage tissue using the grayscale value. These can indicate the potential application of low-field MRI system in providing reliable diagnostic information on cartilage lesion.

ACKNOWLEDGEMENT

This work was supported by Universiti Teknikal Malaysia Melaka (UTeM) and financially supported by the Ministry of Higher Education (MOHE) Malaysia under Fundamental Research Grant Scheme (FRGS/1/2015/TK05/FKM/02/F00272).

REFERENCES

Arencibia, A., Encinoso, M., Jáber, J.R., Morales, D., Blanco, D., Artiles, A., and Vázquez, J.M., 2015. Magnetic Resonance Imaging Study in a Normal Bengal Tiger (Panthera Tigris) Stifle Joint. *BMC Veterinary Research*, 11(1), pp. 184–192.

Blumenkrantz, G., and Majumdar, S., 2007. Quantitative Magnetic Resonance Imaging of Articular Cartilage in Knee Osteoarthritis. *European Cells and Materials*, 13, pp. 75–86.

Braun, H.J., and Gold, G.E., 2012. Diagnosis of Osteoarthritis: Imaging. *Bone*, 51(2), pp. 278–288.

Buckwalter, J.A., and Martin, J.A., 2006. Osteoarthritis. *Advanced Drug Delivery Reviews*, 58(2), pp. 150–167.

Bürk, J., Vicari, M., Dovi-Akué, P., Benndorf, M., Fritz, B., Lenz, P., Niemeyer, P., and Baumann, T., 2015. Extremity-Dedicated Low-Field MRI Shows Good Diagnostic Accuracy and Interobserver Agreement for the Diagnosis of the Acutely Injured Knee. *Clinical Imaging*, 39(5), pp. 871–875.

Cotten, A., Delfaut, E., Demondion, X., Lapegue, F., Boukhelifa, M., Boutry, N., Chastanet, P., and Gougeon, F., 2000. MR Imaging of the Knee at 0.2 and 1.5T: Correlation with Surgery. *American Journal of Roentgenology*, 174(April), pp. 1093–1097.

Crema, M.D., Roemer, F.W., Marra, M.D., Burstein, D., Gold, G.E., Eckstein, F., Baum, T., Mosher, T.J., Carrino, J.A., Guermazi, A., W, F., Marra, M.D., Burstein, D., Gold, G.E., Eckstein, M.F., Baum, T., Mosher, T.J., Carrino, J.A., and Guermazi, A., 2011. Articular Cartilage in the Knee: Current MR Imaging Techniques and Applications in Clinical Practice and Research. *Radiographics*, 31(1), pp. 37–61.

Eckstein, F., Cicuttini, F., Raynauld, J.P., Waterton, J.C., and Peterfy, C., 2006. Magnetic Resonance Imaging (MRI) of Articular Cartilage in Knee Osteoarthritis (OA): Morphological Assessment. *Osteoarthritis and Cartilage*, 14(SUPPL. 1), pp. 46–75.

Egloff, C., Hügle, T., and Valderrabano, V., 2012. Biomechanics and Pathomechanisms of Osteoarthritis. *Swiss Medical Weekly*, 142, pp. 1–14. Fox, A.JS., Bedi, A., and Rodeo, S.A., 2009. The Basic Science of Articular Cartilage: Structure, Composition, and Function. *Sports Health*, 1(6), pp. 461–468.

Gannon, A.R., Nagel, T., and Kelly, D.J., 2012. The Role of the Superficial Region in Determining the Dynamic Properties of Articular Cartilage. *Osteoarthritis and Cartilage*, 20(11), pp. 1417–1425.

Gold, G.E., Chen, C.A., Koo, S., Hargreaves, B.A., and Bangerter, N.K., 2009. Recent Advances in MRI of Articular Cartilage. *American Journal of Roentgenology*, 193(3), pp. 628–638.

Hassanali, S.H., and Oyoo, G.O., 2011. Osteoarthritis: A Look at Pathophysiology and Approach to New Treatments: A Review. *East African Orthopaedic Journal*, 5(2), pp. 51–57.

Hosoda, N., Sakai, N., Sawae, Y., and Murakami, T., 2009. Finite Element Analysis of Articular Cartilage Model Considering the Configuration and Biphasic Property of the Tissue. *IFMBE Proceedings*, 23, pp. 1883–1887.

Iwamoto, M., Ohta, Y., Larmour, C., and Enomoto-Iwamoto, M., 2013. Toward Regeneration of Articular Cartilage. *Birth Defects Research (Part C)*, 99(3), pp. 192–202.

Kersting-Sommerhoff, B., Hof, N., Lenz, M., and Gerhardt, P., 1996. MRI of Peripheral Joints with a Low-Field Dedicated System: A Reliable and Cost-Effective Alternative to High-Field Units? *European Radiology*, 6(4), pp. 561–565.

Liess, C., Lüsse, S., Karger, N., Heller, M., and Glüer, C.G., 2002. Detection of Changes in Cartilage Water Content Using MRI T2-Mapping In Vivo. *Osteoarthritis and Cartilage*, 10(12), pp. 907–913.

Meng, Q., An, S., Damion, R.A., Jin, Z., Wilcox, R., Fisher, J., and Jones, A., 2017. The Effect of Collagen Fibril Orientation on the Biphasic Mechanics of Articular Cartilage. *Journal of the Mechanical Behavior of Biomedical Materials*, 65, pp. 439–453.

Moore, A.C., and Burris, D.L., 2015. Tribological and Material Properties for Cartilage of and throughout the Bovine Stifle: Support for the Altered Joint Kinematics Hypothesis of Osteoarthritis. *Osteoarthritis and Cartilage*, 23(1), pp. 161–169.

Olive, J., 2010. Distal Interphalangeal Articular Cartilage Assessment Using Low-Field Magnetic Resonance Imaging. *Veterinary Radiology and Ultrasound*, 51(3), pp. 259–266.

Pujol, E., Van Bree, H., Cauzinille, L., Poncet, C., Gielen, I., and Bouvy, B., 2011. Anatomic Study of the Canine Stifle Using Low-Field Magnetic Resonance Imaging (MRI) and MRI Arthrography. *Veterinary Surgery*, 40(4), pp. 395–401.

Raynauld, J.-P., 2003. Quantitative Magnetic Resonance Imaging of Articular Cartilage in Knee Osteoarthritis. *Current Opinion in Rheumatology*, 15(5), pp. 647–650.

Tavernier, T., and Cotten, A., 2005. High- versus Low-Field MR Imaging. *Radiologic Clinics of North America*, 43(4), pp. 673–681.